NURSING CARE OF A FAMILY WHEN A CHILD HAS A MUSCULOSKELETAL DISORDER

Chapter 51

OBJECTIVES

- Assess a child with a musculoskeletal disorder.
- Formulate nursing diagnoses related to a child with a musculoskeletal disorder.
- Describe common musculoskeletal disorders in children.
- Establish expected outcomes for a child with a musculoskeletal disorder that help children and parents manage seamless transitions across differing healthcare settings.
- Using the nursing process, plan nursing care that includes the six competencies of Quality and Safety Education for Nurses (QSEN): patient-centered care, teamwork and collaboration, evidence-based practice, quality improvement, safety, and informatics.
- Implement nursing care, such as helping a child with a musculoskeletal disorder meet optimal ambulation capacity. Evaluate expected outcomes for achievement and effectiveness of care.
- Integrate knowledge of children’s musculoskeletal disorders with the interplay of the nursing process, the six competencies of QSEN, and family nursing to promote quality maternal and child health nursing care.

OVERVIEW

- Because their bones and muscles are still growing, children suffer from disorders of the musculoskeletal system more frequently than do adults.
- The difference between adults and children is growth.
- Childhood fractures (break in the continuity or structure of bone) heal much more quickly than fractures do in adults and *because a child's bone grows from the epiphysis or growth plate, a fracture within this area may cause serious complication, such as a malformation*.
- Nurses play a key role in teaching parents whose children have muscular or skeletal disorders that may temporarily or permanently limit mobility how to provide developmental opportunities and promote independence

ASSESSMENT

- Disorders of the skeletal system usually manifest with specific, localized symptoms; therefore, parents usually bring children to healthcare facilities early in the course of such illnesses.
- A limp(walking with difficulty) is never normal, and it may be the first manifestation of a serious hip or knee problem.
- When weighing or measuring children at healthcare visits, take the opportunity to assess gait (whether a child walks naturally or stiffly, on tiptoes or on the whole foot; whether the feet are in good alignment; and whether the spine is straight).
- Such assessments may detect that a child brought to a healthcare center because of an upper respiratory condition, for example, has another, perhaps more important, musculoskeletal problem requiring an evaluation.
- It is also important to note that skeletal injuries can be a sign of child maltreatment; thus, careful history taking is necessary at all health visits

NURSING DIAGNOSIS

- Most frequently identified for children with musculoskeletal disorders include pain and change in the usual form of mobility
- Children, especially adolescents, who require a walker or other assistive devices for a chronic condition, may experience related self-esteem concerns
- Children with musculoskeletal injuries who use crutches or are casted experience a loss of their planned activities and sports participation on a temporary basis
- When a child is immobilized, they often require diversional activities.
  - Pain related to chronic inflammation of joints
  - Impaired physical mobility related to a cast on the leg
  - Diversional activities deficiency related to a need for imposed activity restriction for 4 weeks
  - Situational low self-esteem related to the continuous use of a body brace

OUTCOME IDENTIFICATION AND PLANNING

- Many musculoskeletal problems in children require long-term care.
- Despite current therapies, some disorders may leave a child with a permanent disability.
- Before a child is discharged from an ambulatory or inpatient setting, help parents plan how they will manage any necessary restrictions at home. (if they have long ladders at home to climb – give option like elevator)
- Taking the time to sit down with the parents and asking them whether these concerns will pose problems, however, not only initiates problem solving but also allows parents to prepare solutions with a concerned person rather than by themselves at home.

IMPLEMENTATION

- Many nursing interventions for children with musculoskeletal disorders involve care of a child in a cast or in traction (treatment involving pulling on a body part in one direction against a counterpull exerted in the opposite direction) or teaching about common concerns, such as posture or children’s shoes.
- Parents and children who are well informed are more likely to be able to cope with circumstances that arise.

OUTCOME EVALUATION

- Need follow-up care after discharge from an ambulatory visit or inpatient care because bone healing is a slow process
- Both parents and children may need support at reevaluation visits if they learn that a cast or brace must stay on longer than they thought or if they must continue exercises.
- Praise for their management so far is an effective intervention for helping parents and the child realize that, because they have coped with the situation so far, they can continue to cope with the situation into the future.
- During reevaluation visits, spend time assessing children's body image and self-esteem or the total effect of their condition on growth and development.
- Successful treatment cannot be achieved if a child's self-concept has been diminished by an injury or disease.

BONES AND BONE GROWTH

Review on page 1454

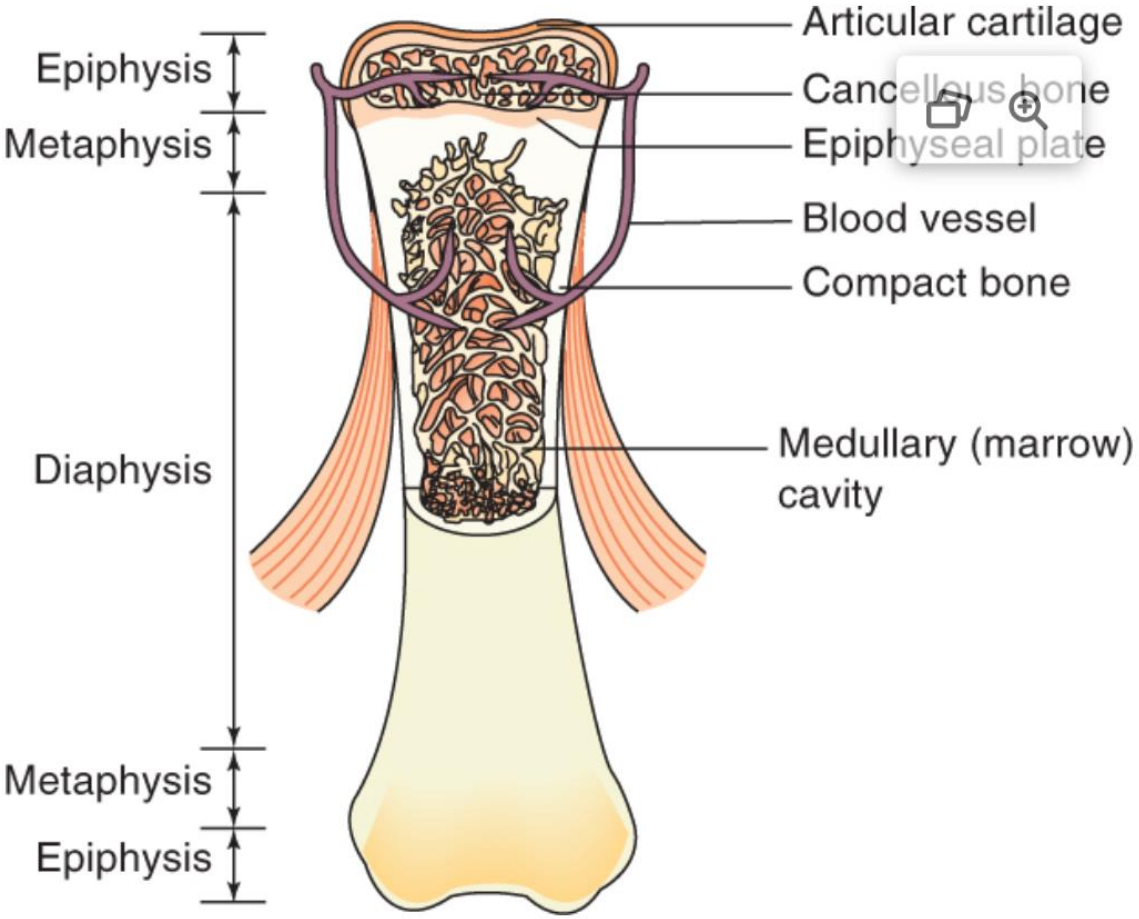

Figure 51.1 The structure of a bone.

ASSESSMENT OF MUSCULOSKELETAL FUNCTION

- Diagnostic tests frequently used to assess musculoskeletal function
  - X-ray, bone scans, bone and muscle biopsies, ultrasound and MRI
- Obtain information on how parents and children are adjusting to a potential disability because poor acceptance of a condition can limit a child's potential as much as the physical involvement (Box 51.2).

HEALTH PROMOTION AND RISK MANAGEMENT

- Focuses on thorough assessment at all well check visits (Gait,spine)
- A child's ability to achieve developmental milestones, specifically gross and fine motor abilities, provides important information about musculoskeletal function.
- Screening for musculoskeletal disorders, such as for scoliosis(bend child and look at spine) in the prepubescent child and the adolescent, is an extremely important health promotion nursing role.
- Safety precautions and anticipatory guidance for parents is essential to minimize the risk of injury, specifically to extremities
- Nutrition education is important to ensure adequate calcium and vitamin D intake for bone growth and healing.
    - However, if a child requires bed rest, calcium intake should be moderated to reduce the risk of renal calculi formation resulting from immobilization.

CASTING

- Casts are used to treat a wide range of musculoskeletal disorders, from simple fractures in the extremities to correction of congenital structural bone disorders
- Fiberglass material is ideal to use for children's casts because it is light in weight; comes in attractive colors; and, when a special waterproof liner is used, can be immersed in water
- Children need an explanation of what to expect with casting
- Allow a support person to accompany children to a cast room to hold their hand or talk to them during the application.
- If a plaster cast is to be applied, caution children that, at first, the wet strips of plaster of Paris feel cool. Almost immediately, however, the strips begin to generate heat as evaporation begins and body parts start to feel warm. If the cast is a full-body cast, children may become uncomfortably warm. Assure them this feeling of warmth is transient and is never enough to cause a burn
- A plaster cast takes 10 to 72 hours to dry depending on its size. Fiberglass casts usually dry within 5 to 30 minutes
- Itching? Use massage or lotion – NEVER stick anything in cast to relieve itching NO HAIR DRYER.



COMPARTMENT SYNDROME

- Phenomenon that can occur when a cast or tight constrictive dressing puts pressure on an enclosed space
- Pressure can result in severely decreased blood flow that potentially threatens damage to and necrosis of surrounding soft tissue or nerves
- Assess fingers or toes carefully for warmth, pain, and function after application of a cast to prevent compartment syndrome from developing – CONFIRM BOTH EXTREMETIES AFTER PUTTING CAST. AND SEE IF BOTH ARE SAME TEMPERATURE AND COLOR.
- If signs of compartment syndrome are present, the cast will need to be released immediately to prevent permanent nerve and tissue damage. A fasciotomy (surgically opening the compartment) may be necessary to further prevent nerve damage
- Assess for color, warmth, presence of pedal or radial pulses, and sensations of numbness or tingling
- Signs of impaired neurovascular function include pallor (including blueness or coldness of the distal part), pulselessness, pain in the casted part, paresthesia (numbness or tingling in the part, as if it were “asleep”), and paralysis

CAST CARE AT HOME

- Keep the casted body part elevated on a pillow for the first day to decrease swelling.
- Observe the hands and fingers (the body part distal to the cast) for swelling or blueness and ask your child to move their fingers about every 4 hours for the first 24 hours.
- If your child is unable to move their fingers or if there is swelling, blueness, or pain, contact your healthcare provider. These signs could mean the cast is pressing on a nerve or constricting a blood vessel.
- Encourage usual activities so that your child remains active and limit strenuous activities while the cast is in place.
- Ask your child to think through how wearing a cast will change their day, such as making it difficult to eat at preschool or to join in play at the playground, and brainstorm how to solve these problems.
- Explain to your child not to put anything inside the cast. If itching occurs, blowing some cool air into it from a hair dryer can be comforting.
- Keep the cast dry (cover it with a plastic bag to shower); **no swimming is allowed.**
- Remind your child not to use magic markers on the cast because fiberglass is a porous material.
- Keep your return appointment for follow-up care because children can outgrow a cast rapidly. Outgrowing a cast can put pressure on nerves and can lead to permanent disability.

MEDICAL BOOTS OR SPLINTS

- In some instances, a fracture does not require a cast for immobility but can be immobilized by a supportive boot or splint.
- The child wears the boot or arm splint continuously as if it were a cast; an advantage is that, if a complication should occur, it can be readily removed by its Velcro attachments.
- Ask at return appointments if children who are prescribed boots or splints are wearing the immobilizer continually.
- This is a disadvantage of the boot or splint because if it is not worn continually, healing may be delayed or disrupted.

CRUTCHES

- Crutches are prescribed for children for one of three reasons:
  - to keep weight off one or both legs
  - to support weakened legs
  - to maintain balance.
- Usually, a physical therapist measures crutch length and gives beginning instruction in crutch walking.
- Being familiar with how crutches are measured and having crutch walking supervised not only allows you to offer emotional support to children as they learn to use crutches but also helps you assess progress at follow-up visits

FIT AND ADJUSTMENT

- Teach children not to rest with the crutch pad pressing on the axilla; they should always support their weight at the handgrip.
- Always assess the tips of crutches to be certain the rubber tip is intact and not worn through because the tip prevents the crutch from slipping.
- Determine that the child is walking with the crutches placed about 6 in. to the side of the foot. This distance furnishes a wide, balanced base for support.
- Before discharge from a healthcare facility, explore with children any problems that crutches may cause with their daily activities.
- If they carry books to school, for example, they will need to wear a backpack so their hands are free for the hand rests.
- Caution parents to clear articles such as throw rugs, small footstools, or toys out of paths at home.

TRACTION

- Traction, which reduces dislocations and immobilizes fractures, involves pulling on a body part in one direction against a counterpull exerted in the opposite direction
- Either skin traction (in which skin provides the counterpull) or skeletal traction (in which bone provides the counterpull) may be used.
- Skin traction is used if only minimal traction is necessary; the child's skin must be in good condition to use skin traction.
- Skeletal traction is used if a longer period of traction or a greater strength of traction pull is required
- Use of traction in the home shortens hospital stays and enables a child to interact with family members, so it should be encouraged when possible.

SKIN TRACTION

- Skin traction means a child's extremity is wrapped in a material such as an elastic bandage and then suspended from a pole or frame, so the weight of the body part produces traction. Bryant traction, used for fractured femurs in children younger than 2 years, is an example of skin traction
- May be used in preparation for surgical repair of congenital developmental disorders, such as developmental hip dysplasia
- Used less frequently now because the elevation of the extremities causes blood to pool at the hips. This and the possible tourniquet effect of the traction strips, bandages, and traction itself increase the risk of vasospasm and avascular hip necrosis
- Buck extension is an example of skin traction used for immobilizing lower extremity fractures in older children.
- Dunlop traction is used to immobilize an upper extremity.
- Cervical skin traction may be used to decrease muscle spasms in the back. This type of traction uses a halter-type device attached to weights. The head of the bed is elevated to provide countertraction.

SKELETAL TRACTION

- Skeletal traction involves the use of a pin, such as a Steinmann pin, or a wire, such as a Kirschner wire, that is passed through the skin into the end of a bone.
- The pin or wire can be inserted in the emergency department under local anesthesia if the child can hold absolutely still, but usually it is done under general anesthesia in the operating room.
- With skeletal traction, ropes strung over pulleys and attached to weights exert a pull on the extremity at the pin site.
- Cotton gauze squares are usually placed around the ends of the pin on the outside.
- The sites are cleaned with the protocol preparation used in the institution using sterile technique to keep them free of drainage.
- Observe pin sites daily for drainage because odorous or excessive drainage or local erythema may be a sign of infection.

TRACTION RELATED CARE

- Needs to be assessed carefully for neurovascular impairment, the same as children in casts
- Assess the extremity in traction every 15 minutes during the first hour, hourly for 24 hours, and every 4 hours thereafter for signs of pallor (or blueness), lack of warmth, tingling, absent peripheral pulse, edema, or pain.
- Traction can lead to hypertension because the head typically is positioned lower than the lower extremities. Assess once a day for this possibility by taking blood pressure readings
- Be extremely careful when changing a child's bed linens or carrying out nursing functions that you do not move the weights or interfere with the traction.
- Provide good skin care on the child's back, elbows, and heels because they may become irritated from friction against the sheets.
- A trapeze bar suspended over the bed provides a great deal of mobility and assists children in using a bedpan or positioning themselves in bed
- Child life specialists or volunteers can be helpful in keeping them engaged and promoting developmental and educational progress. Being certain they are involved in activities (computers or other handheld devices) is an important part of nursing care
- Helping school-aged children and adolescents maintain contact with their friends through cards, letters, recorded messages, social media, or texting is also important

DISTRACTION

- The use of an external device to separate opposing bones, which then encourages new bone growth.
- Can be used to lengthen a bone if one limb is shorter than the other or can be used to immobilize fractures or to correct malformations if the bone is rotated or angled.
- Consists of wires that are inserted through the bone and then attached to either full or half rings, which are secured to telescoping rods. For bone lengthening, the rods are adjusted approximately 1 mm each day to stimulate bone growth until the desired length is achieved. The device remains in place until consolidation is complete; there is no pain, limp, or edema; and the bone is healed and can bear weight.
- Both the child and parents need thorough preparation for the surgery, application of the device, and how it will appear. If desired, provide suggestions for ways to minimize the device's appearance, such as wide-legged pants with adjustable closures. If parents will be adjusting the telescoping rods, providing care to the wire insertion sites, or restricting activity, provide them with complete and clear instructions on what to do as well as how to assess for signs and symptoms of infection. Ascertain that they have follow-up appointments because continued care is essential to ensure an optimal outcome for their child.

DISTRACTION CARE

- Both the child and parents need thorough preparation for the surgery, application of the device, and how it will appear.
- If desired, provide suggestions for ways to minimize the device's appearance, such as wide-legged pants with adjustable closures.
- If parents will be adjusting the telescoping rods, providing care to the wire insertion sites, or restricting activity, provide them with complete and clear instructions on what to do as well as how to assess for signs and symptoms of infection.
- Be certain that they have follow-up appointments because continued care is essential to ensure an optimal outcome for their child.

OPEN REDUCTION

- Open reduction is a surgical technique used to align and repair bone
- Once surgery is completed, the area usually is casted to provide support
- At least a small amount of serosanguineous fluid oozes from the open reduction site into the cast. (SMALL AMT IS NORMAL) IF ITS GROWING LIKE MORE THEN 24 HRS THAN NOTE THAT.
- Outline with a pen or crayon any stain that suggests oozing from a surgical incision, so that an increase in the size of the mark can be detected.
- Do not use a magic marker for this because the fluid tends to penetrate through the cast.
- Add the time at which you make the mark so that you can tell how rapidly the spot is increasing.
- Prone to infection, the same as any child with a surgical incision is, be aware of systemic symptoms (e.g., increased pulse, increased temperature, lethargy) as well as local signs (e.g., edema, pain, tingling, blueness, or coolness of the distal extremity) of infection

GROWING PAINS

- Listen to parents carefully when they state their child has “growing pains” because what they are reporting may be symptoms indicative of rheumatic fever or JIA
- Growing pains occur most frequently in the muscle of the calf, never in a joint.
- Reported most often in preschool- and school-aged children, who wake at night because of the pain
- Cramping usually follows a day of vigorous activity or wearing new shoes with a heel of a different height than before.
- Some children, especially adolescents, who report they have growing pains may actually be reporting restless leg syndrome. (IRRIRESIBLE URGE TO MOVE LEGS)

OSTEOGENESIS IMPERFECTA

- Connective tissue (collagen) disorder in which fragile bone formation leads to recurring (pathologic) fractures
- X-rays reveal a particular ribbonlike or mosaic pattern in their bones, which aids in diagnosis
- Because the child has such frequent injuries, parents may be accused of child maltreatment before the child's condition is firmly diagnosed and documented
- As the child grows older, the multiple breaks tend to cause limb and spinal column deformities, interfering with alignment or growth. Lessened rib motility leads to interference with respirations
- Bisphosphonates are widely used in the palliative treatment of osteogenesis imperfecta with the intention of reducing fracture risk. Bisphosphonates increase bone mineral density (BMD) but do not prevent fractures
- Lightweight leg braces or intramedullary rod insertion techniques may also be prescribed
- Parents need to protect children from trauma, fractures need to be aligned and casted, and children need to be educated about a lifestyle that is productive yet minimizes the risk of trauma

LEGG-CALVE-PERTHES DISEASE (COXA PLANA)

- Avascular necrosis (a lack of blood flow resulting in destruction) of the proximal femoral epiphysis
- Usually occurs unilaterally but may occur bilaterally
- Child is ambulatory and can have a limp, which may be subtle. There is little pain on hip but will have guarding while moving
- X-ray studies distinguish the condition from simple synovitis (inflammation of the hip joint), which begins with the same symptoms. X-ray changes may not be apparent when a child is first seen, but they appear after about 3 weeks. For this reason, most children seen for synovitis of the hip joint are asked to return in 3 weeks for a repeat film.
- Treatment in children younger than 6 years usually focuses on pain reduction with NSAIDs plus keeping the head of the femur within the acetabulum by a containment device
- The acetabulum then acts as a mold to preserve the shape of the femoral head and maintain range of motion.
- In children older than 6 years, reconstructive surgery (an osteotomy to center the femur head in the acetabulum followed by cast application) is most often the course. This technique returns the child to normal activity within 3 to 4 months in contrast to many months of restricted activity required by non–weight-bearing devices

LEGG-CALVES-PERTHES

- Parents and children need thorough education about treatment and care –most of this occurs outpatient
- It can be difficult for young children to accept the extended treatment period involved with this disorder
- Assess that both parents and children understand there are long-term consequences if rest is not followed- MAY NEED HIP SURGERY LATER IN LIFE.
- Without treatment, the femur head tends to remold into a mushroom shape, making the hip unstable thereafter and leading to degenerative changes later in life, which lead to chronic pain, reduced mobility of the hip joint, and, possibly, permanent disability
- Parents may need assistance with devising appropriate activities for the child during the time that activity is limited and weight bearing is not permitted

OSGOOD-SCHLATTER DISEASE

- Thickening and enlargement of the tibial tuberosity resulting from microtrauma probably caused from overuse
- It occurs more often in males and at preadolescence or early adolescence probably because of rapid growth at these times
- Children notice pain and swelling just below the knee that is worse when running or squatting
- Therapy depends on the extent of the bone changes
- Administration of NSAIDs, ice, and limiting strenuous physical exercise may be all that is necessary for effective healing
- Occasionally, immobilization of the leg in a walking cast or immobilizer for about 6 weeks may be required.

SLIPPED CAPITAL FEMORAL EPIPHYSIS

- Slipping or displacement of the capital femoral epiphysis (femoral head) from the femoral neck (metaphysis) through the epiphyseal plate
- Like legg-calve-perthes in beginning
- If the cartilage covering the femur head is destroyed, permanent loss of motion of the femoral head in the acetabulum can result.
- Surgical reconstruction of the hip joint will then be necessary to correct the problem
- Onset of symptoms occurs gradually.
  - Children begin to limp as well as hold the leg on the affected side externally rotated to relieve stress and pain in the hip joint.
  - The involvement is actually in the hip, they may report pain first in the knee because favoring the hip joint puts abnormal stress on the knee.
  - On physical examination, internal rotation of the hip is difficult and painful.
  - An X-ray reveals the slipped epiphysis at the femoral head

SLIPPED CAPITAL FEMORAL EPIPHYSIS

- Early detection is important, before necrosis has occurred
- Percutaneous in situ fixation remains the standard of care for stable slipped capital femoral epiphysis
- In some cases, total hip replacement is necessary
- With either surgery, child will have activity limitations for an extended time
- Most common in preadolescence
- Will not like being confined to bed --> good communication to help them understand
- Encourage visitors

OSTEOMYELITIS

- Infection of the bone
- Acute osteomyelitis is usually caused by Staph or Strep
- Sickle cell have susceptibility to Salmonella in bones
- Can be from infection, penetrating wound, open fracture, or contamination during surgery
- Usually have vague symptoms
  - Malaise
  - Fever
  - Irritability
  - Sharp pain at metaphysis plate

OSTEOMYELITIS

- By second day, usually has fever over area of affected bone, warmth and edema
- Edema formation reduces blood supply to large portion of bone, causing bone death
- Dead bone tissue will appear dense on x-ray and is called sequestrum – important marker for diagnosis
- MRI can show if infection has spread to other soft tissue
- Labs: increased WBC, increased CRP, increased ESR, + blood culture

OSTEOMYELITIS

- Limited weight bearing to affected extremity
- Bed rest and immobilization
- IV Antibiotics started in hospital and then continued at home for about 2 weeks with PICC
- After completion of IV antibiotics, child will complete oral antibiotics for 3-4 more weeks
- Most children recover completely
- If not resolved with initial treatment, it will return and result in chronic infectious process with open, draining sinuses and bone malformation
- Growth plates can be destroyed --> shortening of affected extremity

DISORDERS OF THE SKELETAL SYSTEM

- Kyphosis: an outward curvature of the cervical spine
- Lordosis: an inward curving of the lumbar spine
- Scoliosis: an S-shaped curve
  - Functional: a nonrotated spinal curve caused by a secondary problem, such as a leg length discrepancy
  - Structural: a primary condition such as an underlying neuromuscular disorder

STRUCTURAL SCOLIOSIS

- most common form of scoliosis occurs in or near adolescence and is termed idiopathic scoliosis
- As long as the child is growing, the spinal curves will become more severe, which is why the symptoms become most marked at prepuberty (a time of rapid growth).
- If the child bends forward (Adams test), the curve becomes even more noticeable.

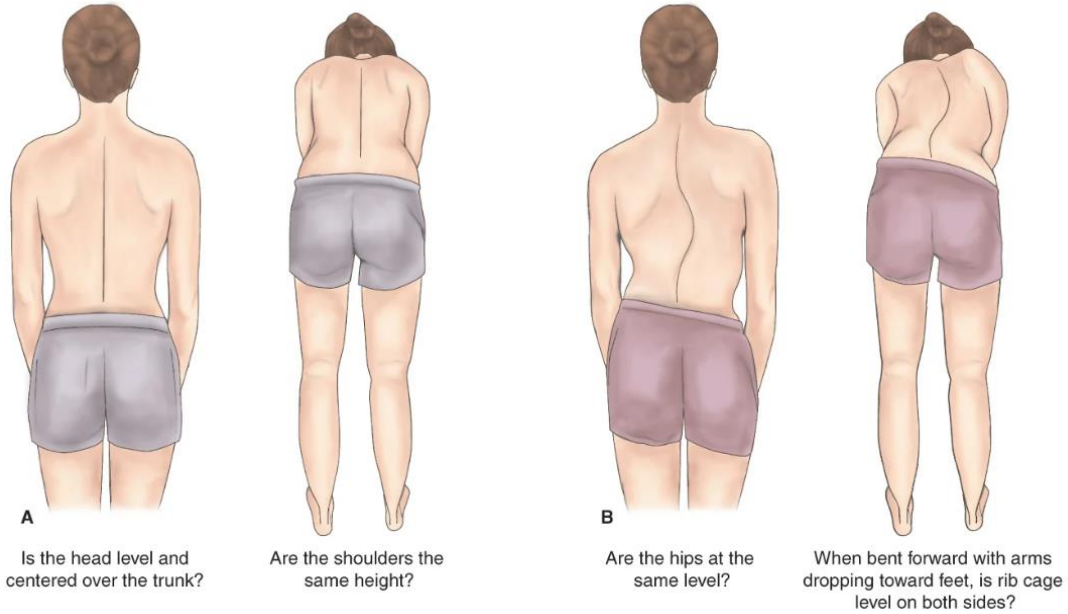

SCOLIOSIS ASSESSMENT

- American Academy of Pediatrics (AAP) believe that screening examinations should be part of the medical home preventive services visit for females at age 10 and 12 years and for males at age 13 or 14 years
- Often, the condition develops insidiously and is prominent before it is noticed because of the preadolescent's and adolescent's desire for privacy and the lack of pain that accompanies the condition. A parent might notice when doing laundry that a child's bra straps are adjusted to unequal lengths. A child may find it difficult to buy jeans that fit correctly because of uneven iliac crests or may notice that clothing hangs unevenly
- A scoliometer is a commercial device used to document the extent of a spinal curve.
- MRIs, X-rays, and CT scans all play a role in estimating the extent of the condition and in providing a baseline description
- If the child has a vertebral rotation causing rib imbalance, pulmonary function studies and a chest X-ray may be obtained to document the effect on lung capacity
- The X-ray to identify scoliosis is obtained in the standing position

SCOLIOSIS MANAGEMENT

- Usually, if the spinal curve is less than 20 degrees, no therapy is required except for close observation and X-rays about every 6 months until the child reaches growth maturity
- If the curve is greater than 20 degrees, treatment can consist of a conservative, nonsurgical approach using a body brace; it could include surgery or a combination of both surgical and nonsurgical measures
- Curves greater than 40 degrees may require surgery with spinal fusion
- The goal of both surgery and mechanical bracing is to maintain spinal stability and to prevent further progression of the condition until bone growth is complete
- Regardless of the type of treatment chosen, the child and family must be prepared for long-term treatment
- During prepuberty and adolescence, children tend to be very concerned about body image and so can become resistant to treatment for scoliosis correction

SCOLIOSIS BRACING

- For slight spinal curves in a child who is still skeletally immature
- The Milwaukee brace was the first type used for this purpose, so, although today's braces look much different, they may still be referred to by this name
- Braces are now designed by computer-aided techniques to ensure that the brace will be both comfortable and will accomplish maximum correction
- The brace is worn for 23 hours per day, removed only for showering or participation in a structured athletic program
- At night, a child may use a Charleston bending brace that confines the spine to an overcorrected position.
- Assess whether children and parents know how to safely apply these braces
- Frequent follow-up healthcare visits are necessary to check that the device still fits snugly without rubbing on bony prominences, such as the iliac crests

SCOLIOSIS BRACING

- Caution children and parents not to loosen straps if rubbing occurs because this causes the brace to fit loosely, thus not allowing it to exert adequate compression and traction on areas that are curved
- Alert parents and children to notify their healthcare provider instead
- Assess that the child is wearing the brace over a T-shirt to prevent the plastic pads from touching skin surfaces and causing skin excoriation
- During the first couple of weeks that they wear a brace, children may notice slight muscle aches resulting from the new straighter back alignment
- A mild analgesic such as acetaminophen (Tylenol) will decrease this discomfort in most children
- Rest also provides considerable relief
- Caution children not to remove the brace during this time because taking it off compounds the problem of discomfort by prolonging the period of adjustment

SURGICAL INTERVENTION – SURGICAL INSTRUMENTATION

- Surgical correction usually is necessary if the spinal curvature is greater than 40 degrees. Instruments such as rods and screws are placed next to the spinal column to provide firm reduction of the curvature; the spine is fused in the corrected position
- A disadvantage of fusion is that it prevents further spinal growth and limits motion of the lumbar section if involved—a concern that can be solved by the use of fusionless interventions such as intervertebral stapling or expandable rods

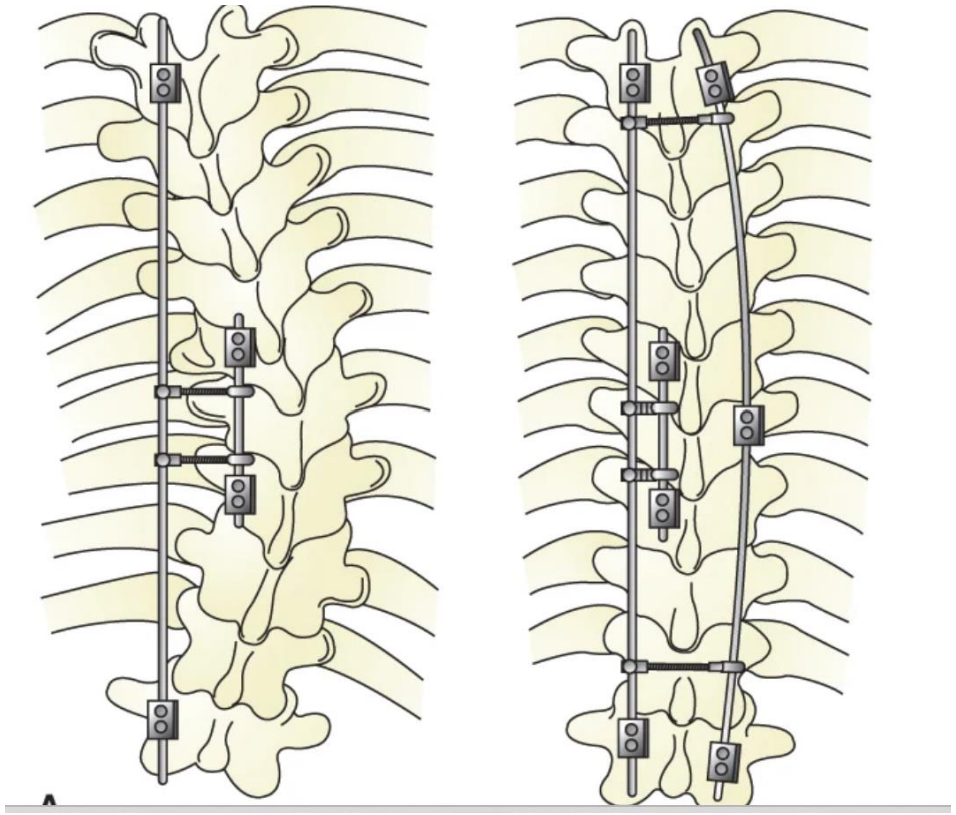

PREOPERATIVE CARE

- Ensure children have a good explanation of what they can expect before and after surgery
- Deep breathing and incentive spirometry are important
- Place a nasogastric tube before surgery to prevent abdominal distention
- Pain control is important
  - Epidural anesthesia offers a great deal of pain relief
  - Allowing children to use an IV or epidural patient-controlled analgesia system offers both pain relief and a feeling of control.

POSTOPERATIVE CARE

- Repositioning is important to prevent pressure areas and to maintain care of instrumentation – LOG ROLL!
- Incision assessment, vital signs, neuro assessments and pain control
- Careful neurologic assessment of upper and lower extremity function should be continued for at least 48 hours after surgery
- Children are usually prescribed nothing by mouth until bowel sounds return (usually 12 to 24 hours)
- An indwelling urinary catheter, placed during surgery, is usually left in place for 24 hours because voiding may be difficult - also allows for an assessment of kidney function
- As soon as bowel sounds are present, a child can begin to take fluids and then solids
- Usually on day 1 post-op, PT is initiated to help children learn how to change position and ambulate
  - They may feel dizzy at first; therefore, allow them to get used to sitting by attempting it for only short periods at a time at first. Activity is then increased to a normal level with few restrictions.
- Removing rods is as extensive a procedure as inserting them, instrumentation rods are left in place permanently unless they cause irritation or infection later

HALO TRACTION

- Halo traction is the use of opposing forces to straighten and reduce spinal curves that are severe when first diagnosed (over 80 degrees) or that are progressing despite bracing
- Halo traction is achieved using a ring of metal (a halo) held in place with about four stainless steel pins inserted into the skull bones
- Pins inserted into the distal femurs or the iliac crests apply countertraction
- children need to see photographs of the apparatus or should be able to talk to children who have the apparatus in place before having it applied
- Need frequent care at the pin sites according to practitioner or hospital policy
- In the absence of skin sensitivity, pin site care should be undertaken at least once a week using the protocol-approved solution or as often as necessary to keep the area clean
- A daily shower with regular shampoo is also recommended to provide further pin cleaning
- Encourage children to be self-sufficient and do as many things as they are able
- After optimal spinal correction has been achieved with the device, the equipment is easily removed. The pin sites in the skull heal within 1 week without obvious scarring

JUVENILE IDIOPATHIC ARTHRITIS

- Primarily involves the joints of the body, although it also affects blood vessels and other connective tissues
- Includes children younger than 16 years who have chronic arthritis (swelling or effusion, or presence of two or more of the following signs: limitation of range of motion, tenderness or pain on motion, and increased heat) in one or more joints (lasting more than 6 weeks) and in whom no other specific cause of arthritis can be identified
- The cause of JA is unknown, although it is thought to be an autoimmune process in which a child develops circulating antibodies (immunoglobulins) against body cells
- Usually seek healthcare due to persistent fever and rash, symptoms that present even before the pain and stiffness of joint involvement begins
- Assess children for the effect their disease is having on self-care. Do they need help eating, dressing, ambulating, or toileting?

JIA MANAGEMENT

- JA is a long-term illness, therapy includes a balanced program of exercise, rest, and medication administration to relieve pain, restore function, and maintain joint mobility
- Children are prescribed a set program of daily range-of-motion exercises designed to strengthen muscles and put joints through their full range of motion
- Encourage children to do as much self-care as they can because the natural motions of activities such as dressing and brushing teeth exercise joints
- Activities that place excessive strain on joints, such as running, jumping, prolonged walking, and kicking, should be avoided
- Need to still attend school, but may need to shorten the day due to fatigue
- Heat application
  - Heat reduces pain and inflammation in joints and so increases comfort and motion
  - Heat can be applied using a heating pad or warm water soaks for 20 to 30 minutes

JIA MEDICATION

- NSAIDs such as ibuprofen (Motrin) or naproxen (Naprosyn) are the analgesics of choice
- Educate parents that they should continue to give the drug even if the child has no noticeable pain at the time of administration because the drug's anti-inflammatory action is just as important as its pain prevention
- Methotrexate, a cytotoxic drug, is the second drug usually prescribed
- Steroids, such as prednisone, are added if the disease is extremely severe or is an incapacitating systemic disease that has not responded to other anti-inflammatory agents
  - Steroids are injected directly into the affected joint
- Meds called tumor necrosis factor (TNF) inhibitors, such as etanercept (Enbrel) or infliximab (Remicade)
  - Reduce inflammation by blocking the action of TNFs, which cause inflammation
  - Etanercept is injected subQ every week, so parents need detailed instructions on the technique to do this as well as the importance of guarding against infections because children are more susceptible than usual to infection while taking these drugs
  - Infliximab is given IV and usually requires a short-term healthcare facility stay

MYASTHENIA GRAVIS

- With Myasthenia gravis, interference in ACh processing leads to symptoms of progressive muscle weakness or inability to contract
- Occurs most often from an autoimmune process where autoantibodies may block receptor sites for ACh or other receptors such as muscle-specific kinase (MuSK) receptors
- Occurs in three forms in childhood: neonatal transient myasthenia, congenital myasthenia, and juvenile myasthenia
- Children gradually begin to develop double vision (diplopia) and ptosis because of weakness of the extraocular muscles. Symptoms grow intense as facial, neck, jaw, swallowing, and intercostal muscles become affected. Fatigue is extreme, becoming more noticeable as a day progresses. All symptoms increase with emotional stress, fatigue, menstruation, respiratory infections, and alcohol intake. In the most severe form, all muscles, including those of respiration, become unable to contract
- Obtaining an accurate history, especially documenting whether a child can perform repetitive movements, is important. Ask a child to look upward and hold that position. Children with myasthenia gravis, unlike others, will gradually demonstrate ptosis. Most children have myography performed to document their poor muscle function. An MRI or a CT scan demonstrates the enlarged thymus gland
- Edrophonium (Tensilon) is a drug that prolongs the action of ACh and therefore increases muscle strength. If the child's muscle strength improves moments after an injection, the child's diagnosis is positive for myasthenia gravis

MG MANAGEMENT

- Goal of treatment for myasthenia gravis is to improve the strength and endurance of a patient by facilitating neuromuscular transmission
- Treated by the administration of neostigmine (Prostigmin) or pyridostigmine bromide (Mestinon), acetylcholinesterase inhibitors that prolong the action of ACh
- Excision of the thymus gland may reduce symptoms - this is a last resort because it may leave the child open to additional autoimmune disorders in the future
- Teach parents and children that symptoms become worse under stress
- Help children plan their day to include rest periods, possibly advocating for a special school schedule if necessary
- If chewing and swallowing are difficult, ensure a rest period before meals
- If symptoms of muscle weakness suddenly become very severe, parents should call 911 because the loss of function of intercostal muscles may lead to respiratory arrest.
- Atropine, an anticholinergic agent, and the antidote for an overdose of anticholinesterase drugs, should be available to administer as necessary both for parents at home and on a hospital unit that cares for children with this disease

NEOSTIGMINE (PROSTIGMIN)

NEOSTIGMINE (PROSTIGMIN)

Classification: Neostigmine is a cholinesterase inhibitor that acts as an antimyasthenic agent.

Action: Neostigmine increases the concentration of acetylcholine at nerve endings, prolonging and exaggerating its effects and facilitating neuromuscular transmission (Karch, 2020).

Pregnancy Risk Category: C

Dosage: Orally, 2 mg/kg daily in divided doses every 3 to 4 hours; or 0.01 to 0.04 mg/kg per dose intramuscularly, intravenously, or subcutaneously every 2 to 3 hours, as needed

Possible Adverse Effects: Salivation, dysphagia, increased peristalsis, cardiac arrhythmias, increased respiratory secretions, urinary frequency, pupil constriction, and diaphoresis

Nursing Implications

- Assess the child for increased muscle weakness, indicating possible cholinergic crisis. Keep atropine sulfate readily available as the antidote.
- If giving neostigmine orally, administer the drug with food or milk to minimize gastrointestinal upset. Instruct parents to administer the drug exactly as prescribed.
- Plan to administer larger portions of the divided doses approximately one-half hour before anticipated times of greater fatigue.
- Advise parents to watch for signs of excessive salivation, emesis, or frequent urination and to notify their healthcare provider if these occur.
- Encourage parents to control the child's environmental temperature as much as possible to prevent diaphoresis from too hot or too humid an environment.
- Inform parents that an increase in muscle weakness may be related to either drug overdose or exacerbation of the disease. Urge them to report any signs of increased weakness to their healthcare provider immediately.

THE MUSCULAR DYSTROPHIES

- Group of more than 30 genetic diseases characterized by progressive weakness and degeneration of the skeletal muscles that control movement
- Duchenne muscular dystrophy is caused by an absence of dystrophin (a protein in the muscles) that is necessary for muscle contraction due to genetic mutation
- Muscular dystrophies seen in children are classified into three main types: congenital myotonic dystrophy, facioscapulohumeral muscular dystrophy, and pseudohypertrophic muscular dystrophy (Duchenne disease)
- Duchenne disease, the most common form of muscular dystrophy, is inherited as a sex-linked recessive trait. Therefore, it occurs only in males; females who carry the gene may demonstrate some symptoms.
- Symptoms are usually apparent by 3 years of age

DUCHENNE MUSCULAR DYSTROPHY

- Usually have a history of meeting motor milestones, such as sitting, walking, and standing, but they reach these milestones later than does the average infant
- As the disease progresses, muscle weakness becomes more and more pronounced
- Scoliosis of the spine and fractures of long bones may occur from abnormal muscle tension and lack of muscle support
- By early adolescence, the child may become wheelchair dependent
- Tachycardia can occur as the heart muscle weakens and enlarges
- Pneumonia develops easily as the child's cough reflex becomes weak and ineffective
- Death from pulmonary dysfunction tends to occur at about 20 years of age
- Diagnosis is based on the history and physical findings, a muscle biopsy showing fibrous degeneration and fatty deposits, electromyography showing a decrease in amplitude and duration of motor unit potentials, an increased concentration of serum creatine phosphokinase, and genetic analysis

DUCHENNE MUSCULAR DYSTROPHY MANAGEMENT

- Encourage children with muscular dystrophy to remain ambulatory for as long as possible by a program of active and passive daily range-of-motion exercises
- Splinting and bracing may be necessary to maintain lower extremity stability and to avoid contractures
- If children become overweight, remaining ambulatory becomes even more difficult for them - encourage a low-calorie, high-protein diet to avoid excessive weight gain
- To prevent constipation because of poor abdominal muscle tone, encourage a high intake of fiber and fluids
- A stool softener may be necessary
- Corticosteroid therapy is helpful to increase function and strength at least on a short-term basis; help parents understand the importance of this and have a set schedule of administration
- Newer therapies include cell repair, gene transfer, and stem cell

FRACTURES

- Break in the continuity or structure of bone
- Children experience falls during their growth years, fractures of long bones are common childhood injuries
- Bone in childhood is fairly porous, allowing bones to bend rather than break
- The periosteum is thick, so the bone may not break all the way through
- Epiphyseal lines may cushion a blow so that the bone does not break
- Healing is rapid because of overall increased bone growth.
- Greenstick fractures (one side of a bone is broken; the other is only bent) very common - cause minimal pain, swelling, or malformation
- Many fractures in children, however, occur at the epiphyseal line.
- These types of fractures can be serious because bone growth occurs at this point. Damage to the area can lead to undergrowth, overgrowth, or uneven growth, resulting in angulation.

Type of Fracture	Description
Plastic deformation (bend) 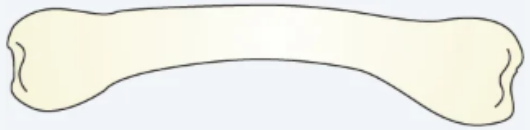	Bone bends, causing a microscopic fracture line that does not cross the bone; most common in the ulna and fibula
Buckle (torus) 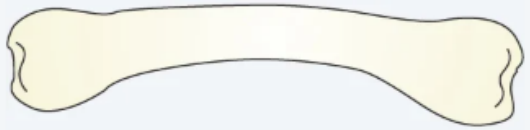	Fracture on the tension side of the bone near softened metaphyseal bone, causing a buckling and raised area on the harder diaphyseal bone (opposite side)
Greenstick	Bone bent with fracture beginning but not crossing through the bone
Complete 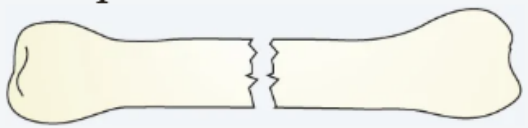	Bone divided (transversely [crosswise at a right angle to the long axis of bone], obliquely [slanted but straight], or spirally [slanted and circular]); bone remnants possibly attached by a periosteal hinge

FRACTURES COMPLICATIONS

- Fat embolism: the release of fat from the marrow of the broken bone into the bloodstream. This embolus then travels to the cerebral vessels and causes symptoms such as confusion or hallucinations as the oxygen supply to brain cells is shut off
- Pulmonary embolism: produces dyspnea, tachycardia, and cyanosis
- Compartment syndrome: If lots of edema present in the injured part, a splint or a cast may be applied but split or bivalved on each side to allow for swelling to decrease to avoid compartment syndrome
- If the growth plate was severely involved in the injury, some children may need bone-lengthening or bone-shortening procedures later in life to ensure equal and adequate bone growth

FRACTURES ASSESSMENT

- Hallmark signs of fracture (malformation, edema, and pain).
- If fracture is suspected, splint the extremity to avoid further trauma
- Splinting also reduces pain because it prevents further movement of the bone
- Splints should extend from a joint above to a joint below the suspected fracture site to prevent movement and muscle tension, which could cause further dislocation of the fracture.
- If an extremity is so seriously deformed by the break that it will not conform to the contour of a splint, do not attempt to move it into a splint position
- Immobilize the extremity by placing sandbags on the sides of the arm or leg and leave it in that position
- Obtain a thorough history of how the fracture occurred – rule out maltreatment

FRACTURE MANAGEMENT

- All children with a suspected fracture need an X-ray to confirm the diagnosis and to determine the alignment
- If skin over the fracture site has been broken, the child may need tetanus prophylaxis and IV antibiotics
- A hematocrit determination to estimate blood loss and cross-matching for replacement therapy may be necessary if a long bone such as a femur was fractured in trauma
- Pain control
- Emotional support

VOLKMANN ISCHEMIC CONTRACTURE

- When an arm is flexed and put into a cast, the radial artery and nerve can be compressed at the elbow, causing nerve injury or severe impairment of circulation. If symptoms of compression are present but not detected within 6 hours, Volkmann contracture and possible permanent damage to the arm will result.
- The arm is left permanently flexed at the elbow. The wrist is hyperextended, and the fingers assume a flexed, clawlike, and useless position.
- If a child is going to be discharged from a healthcare facility after application of a cast, inform parents about the symptoms of compression so they can continue to assess for its development.
- If a child is admitted to the hospital after cast application, the radial pulse (if palpable at the edge of the cast) should be taken hourly, along with checks for coldness, blanching, and color of the fingers, during the first 8 hours.
- In some instances, a cast is applied incompletely for 24 hours, the elbow portion being simply splinted and wrapped with elastic bandages. After 24 hours, when edema has subsided and the chance of compression is less, the rest of the arm is then casted